



**PRESENTING CLINICAL SIGNS**

History: Grade 2-3/6 left-sided murmur. Pre-anesthetic evaluation (neuter).

**DATE**

7/28/22

**ECHOCARDIOGRAPHIC FINDINGS**

2D, M-mode, and Doppler study.

**PERFORMED BY:**

Kelly Vazquez

**INTERPRETED BY**

Keith Blass, DVM,  
MS, DACVIM  
(Cardiology)

Left atrial size is normal. The mitral valve is normal. Left ventricular wall thickness is normal. Left ventricular internal dimensions are normal. Left ventricular systolic function is normal. The aorta and aortic valve appear normal, though there is mildly increased velocity laminar flow in the ascending aorta. Right atrial and right ventricular dimensions are normal. The tricuspid valve appears normal, though trace tricuspid regurgitation is present. The pulmonary artery and pulmonic valve appear normal, though trace pulmonic insufficiency is present. No shunting lesions are visualized. No pericardial effusion or cardiac masses are seen.

**PATIENT**

Duke Martinez

LA - 36.1 mm  
IVSd - 8.8 mm  
LVPWd - 8.8 mm  
LVIDd - 39.1 mm  
LVIDs - 26.4 mm  
FS - 32.5%  
RA - 25.4 mm  
LVOT - 1.81 m/s  
RVOT - 1.41 m/s

**SPECIES**

Canine

**BREED**

Dogo Argentino

**ASSESSMENT/RECOMMENDATIONS**

Duke's murmur appears to be due to the presence of mildly increased flow velocity in his ascending aorta. As Duke is already 5 months old and the flow appears to be laminar, it's very likely that this represents a functional/innocent increase in flow velocity, though, the presence of mild subaortic stenosis cannot be definitively ruled out until Duke is fully grown.

Duke's cardiovascular risk for general anesthesia is low based on this exam, and there are no contraindications to the use of any specific anesthetic agents.

**SEX**

No therapy is recommended based on this exam.

**MI**

A recheck echocardiogram may be warranted in 7-9 months to make sure that Duke's aortic flow velocity remains below the threshold to be consistent with subaortic stenosis (~2.5 m/s).

**AGE**

5 mo

**WEIGHT**

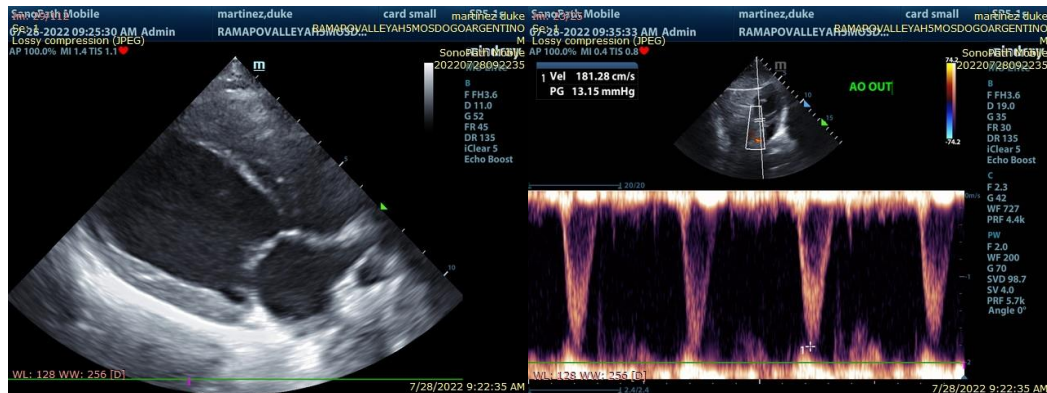
56.6 lb

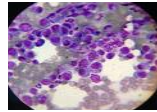
**HOSPITAL NAME**

Ramapo Valley AH

**REFERRING VET**

Dr. Katara





**DATE**

7/28/22

**PERFORMED BY:**

Kelly Vazquez

**INTERPRETED BY**

Keith Blass, DVM,  
MS, DACVIM  
(Cardiology)

The information and recommendations provided are based on the images presented by the referring veterinarian. No evaluation can be communicated regarding pathology that was not visible in the image/video clips provided.

Thank you for this referral. If the clinical or image interpretation does not parallel your findings or if I can be of any further assistance please contact me.

**Keith Blass, DVM, MS, DACVIM (Cardiology)**  
KeithBlass@gmail.com  
631-804-5754

**PATIENT**

Duke Martinez

**SPECIES**

Canine

**BREED**

Dogo Argentino

**SEX**

MI

**AGE**

5 mo

**WEIGHT**

56.6 lb

**HOSPITAL NAME**

Ramapo Valley AH

**REFERRING VET**

Dr. Katara